



EDMONTON

DIAGNOSTIC IMAGING INC.
ORAL & MAXILLOFACIAL

Callingwood Square Shopping Centre
6641-177 Street, Edmonton, Alberta T5T 4K3
Phone: (780) 483-1338 Fax: (780) 483-1393
Email: info@edxi.com Website: www.edxi.com

Patient:
Date of Images:
Referring Dr.:
Date of Report:

Age:

Sex:

This report is based on an iCAT- cone beam CT of the temporomandibular joints (TMJs) in the closed mouth position. Field of view extends from the roof of orbits superiorly the level of C3 inferiorly. The purpose of this study was to assess both TMJs. Reformatted images in the sagittal, coronal and axial planes were viewed.

Radiographic findings:

Right TMJ

The condylar head is centered within the glenoid fossa. The total joint space is within the range of normal. There is mild subchondral sclerosis of the glenoid fossa and articular eminence. There is large cortical erosion along the articular surface of the glenoid fossa, closer to the articular eminence. This is atypical location of cortical erosions.

The contours and cortical boundaries of the osseous structures of the condylar head are within normal.

Left TMJ

The condylar head is inferiorly positioned within the glenoid fossa. The total joint space appears large. This is suggestive of anterior disc displacement.

There is mild flattening of the superior surface of the condylar head with intact cortical boundaries.

The contours and cortical boundaries of the osseous structures of the condylar head, glenoid fossa and articular eminence are within the range of normal.

Other findings:

- Bilateral hyperplasia of the coronoid process.
- Osteoarthritis of the cervical vertebrae (C1 through C2/C3).
- C2 and C3 congenitally fused at the left transverse process.
- Bilateral mucositis of the maxillary sinuses.
- Narrowed upper airway (at naso-opharyngeal junction) due to large soft palate.
- #48 horizontally impacted.

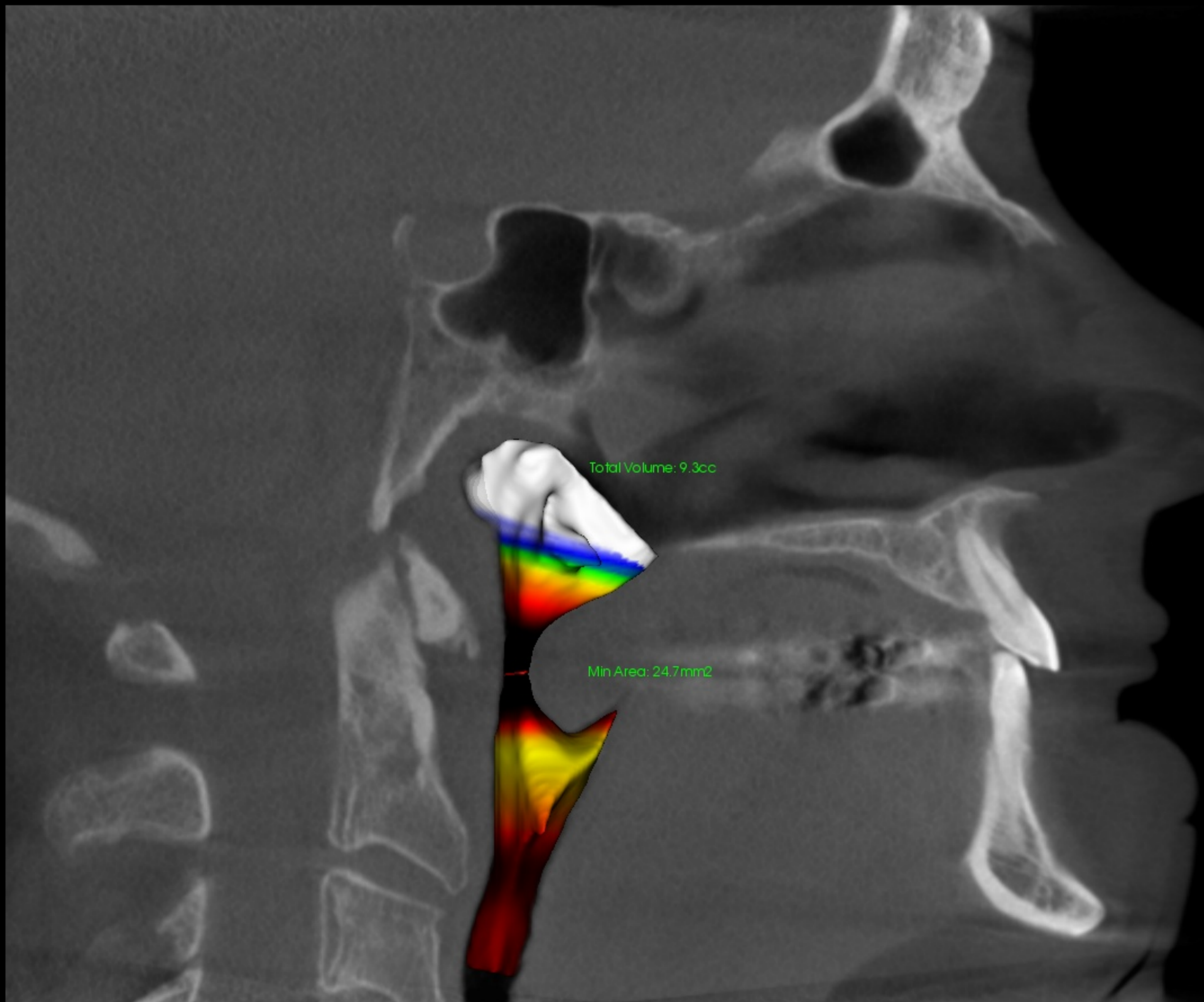
Interpretation:

1. Degenerative joint disease in the right TMJ, with atypical presentation.
2. Early physiologic remodeling in the left TMJ

This radiographic investigation does not rule-out abnormalities of the intra-articular disc.

Sincerely,

Noura Alsufyani, B.D.S., M.Sc., F.R.C.D.(C)
Oral and Maxillofacial Radiologist



Total Volume: 9.3cc

Min Area: 24.7mm2

50.0

100.0

150.0

200.0

250.0

300.0

350.0