

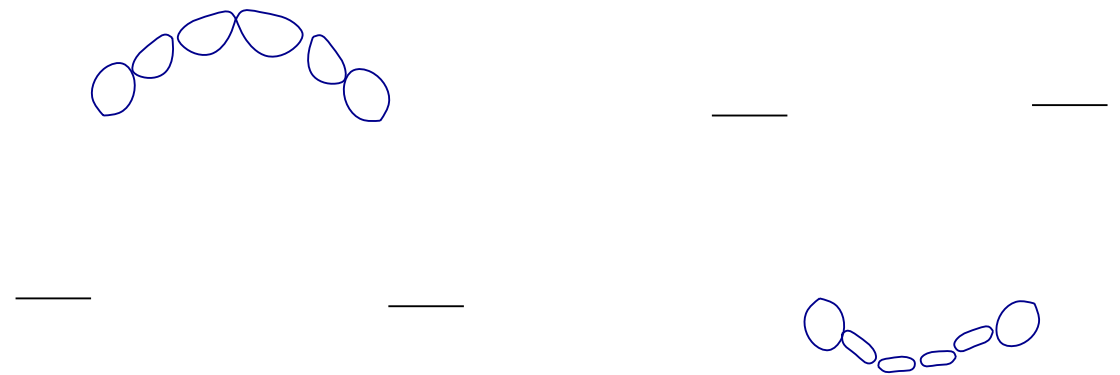
Patient: T F, ID: 853724, Male, Age: 16y 3m (DOB: 26/01/2000)

20/05/2016 Initial Records Analysis: Bolton - Anterior

	Value	Norm	Std Dev	Dev Nor
Maxillary Tooth Widths				
Upper Right Central Incisor (mm)	8.2	8.8	1.0	-0.6
Upper Left Central Incisor (mm)	9.2	8.8	1.0	0.4
Upper Right Lateral Incisor (mm)	6.9	7.0	1.0	0.0
Upper Left Lateral Incisor (mm)	7.2	7.0	1.0	0.2
Upper Right Canine (mm)	7.3	7.9	1.0	-0.6
Upper Left Canine (mm)	7.6	7.9	1.0	-0.3
Max. Anterior Total Widths (mm)	46.4	47.4	N/A	N/A

Mandibular Tooth Widths				
Lower Right Central Incisor (mm)	4.9	5.4	1.0	-0.5
Lower Left Central Incisor (mm)	4.7	5.4	1.0	-0.7
Lower Right Lateral Incisor (mm)	5.7	5.9	1.0	-0.3
Lower Left Lateral Incisor (mm)	5.5	5.9	1.0	-0.4
Lower Right Canine (mm)	7.0	6.9	1.0	0.0
Lower Left Canine (mm)	6.8	6.9	1.0	-0.1
Mand. Anterior Total Widths (mm)	34.6	36.6	N/A	N/A

Bolton Ratio (Md/Mx) (%) 74.6 77.2 1.0 -2.6 **
Mandibular Tooth Size Excess (mm) -0.7 2.0 2.0 -1.3 *



******* These images are predictions only ----actual treatment results may vary*****
Edmonton Diagnostic Imaging (780) 483-1338 www.edxi.com**